



**PATIENT**

Bismarck Gleichmann

**SPECIES**

Canine

**BREED**

Australian Cattle Dog

**SEX**

Male Neutered

**AGE**

13 years

**WEIGHT**

34lbs

**INTERPRETED BY**

Maggie Machen Lamy,  
DVM, DACVIM  
(Cardiology)

**IMAGING PERFORMED BY**

Cole England, DVM

**HOSPITAL NAME**

Blue Cross Animal  
Clinic

**REFERRING VET**

Dr. Aguirre

**INVOICE**

47254

**DATE**

3/23/26

**PRESENTING CLINICAL SIGNS**

History: Recheck echo. History of murmur, arrhythmia, and hepatopathy. Grade 4/6 heart murmur. Doing well. On Sotalol 20mg q12h.

-Abnormal PE/Chem/CBC/UA Results: ALT 300, ALP 826, GGT 59, TBil 0.4, TP 8, ALB 4.4, Ca 11.9 - all other chem, cbc, HWT, and T4 findings are normal.

-Pertinent previous echo findings (2/2024 SK) CVD B1. LA/AO: 1.3. Normal function. Ventricular arrhythmias noted; single and couplet VPCs. Holter monitor recommended.

**ELECTROCARDIOGRAPHIC FINDINGS**

A brief six lead ECG is available at 50mm/s; 10mm/mV. The average heart rate is 120bpm. The rhythm is sinus in origin, with a p for every QRS complex and vice versa. The P wave morphology is positive with a normal dimension. Normal PR. The QRS is isoelectric. The MEA is shifted left. Single and couplet VPCs are identified. No APCs, pauses or other dysrhythmias observed.

ECG diagnosis: Normal sinus rhythm with respiratory variation. Left axis deviation. Single and couplet VPCs.

**ECHOCARDIOGRAM FINDINGS**

2D, m-mode, color flow and doppler imaging is available. Mild diffuse thickening of mitral valve leaflets with mild prolapse into the left atrial lumen. Mild mitral regurgitation with mild left atrial dilation. Normal MR velocity. Normal LV diameter with adequate myocardial function. The tricuspid valve appears normal with no tricuspid regurgitation. Normal right atrial and ventricular diameter and morphology indicating no overt evidence of pulmonary arterial hypertension. The pulmonic and aortic valves are normal in morphology and mobility. Normal pulmonic and aortic outflow velocities with laminar flow. No obvious aortic or pulmonic insufficiency. No pericardial or pleural effusion noted. No obvious cardiac masses.

**CARDIAC CHART**

CANINE CARDIAC PARAMETERS	MR VMAX (m/s)	TR VMAX (m/s)	LA/AO (Boon method)	LA/AO (Heart Base; Swe)	FS (%)	EF (%)	EPSS (cm)
<b>NORMAL PARAMETER</b>	4.5-5.5	<2.7	1.3	<1.6	28-40	40-100	<0.6
<b>PATIENT</b>	5.5	NA	NM	1.4	42	78	0.4
CANINE CARDIAC PARAMETERS	HR (BPM)	AV VMAX (m/s)	PV MAX (m/s)	BODY WEIGHT (kg)	LA 2D short axis Base view (cm)	LVIDd Avg; 2D and m-mode short axis (cm)	LVIDs Avg; 2D and m-mode short axis (cm)
<b>NORMAL PARAMETER</b>	50-100	0.7-1.7	0.7-1.6	BELOW	BELOW	BELOW	BELOW
<b>PATIENT</b>	NM	0.5	1.1	15.4	2.9	3.8	2.2
*Normal chamber parameters expressed as a mean value (SD)				3	1.27 (5.3)	2.46 (2.46)	1.36 (5.5)
<b>BODY WEIGHT DEPENDENT PARAMETERS</b>				5	1.40 (4.5)	2.74 (5.2)	1.60 (4.7)
*Note: All measurements based upon multi-modal images and methods. An average value is reported.				10	1.50 (3.8)	3.27 (3.5)	2.06 (3.1)
				15	1.83 (2.0)	3.71 (2.4)	2.43 (2.1)
				20	2.02 (1.9)	4.14 (2.2)	2.80 (2.0)
				25	2.18 (2.4)	4.48 (2.9)	3.10 (2.5)



**PATIENT**

Bismarck Gleichmann

**SPECIES**

Canine

**BREED**

Australian Cattle Dog

**SEX**

Male Neutered

**AGE**

13 years

**WEIGHT**

34lbs

**INTERPRETED BY**

Maggie Machen Lamy,  
DVM, DACVIM  
(Cardiology)

**IMAGING PERFORMED BY**

Cole England, DVM

**HOSPITAL NAME**

Blue Cross Animal  
Clinic

**REFERRING VET**

Dr. Aguirre

**INVOICE**

47254

**DATE**

3/23/26

Adapted from June Boon, Veterinary Echocardiography, 1998 Rishniw M and Hollis NE, J Vet Intern Med 2000; 14:429-435 Hansson et al, Vet Rad and Ultrasound 2002 Bonagura et al. Echocardiography: principles of interpretation, Vet	30	2.33 (3.3)	4.83 (3.9)	3.39 (3.4)
	35	2.48 (4.3)	5.17 (5.0)	3.69 (4.5)
	40	2.62 (5.2)	5.48 (6.1)	3.96 (5.4)
	50	2.88 (7.1)	6.07 (8.3)	4.46 (7.4)

**INTERPRETATION OF THE FINDINGS & FURTHER RECOMMENDATIONS**

Chronic degenerative valve disease causing mild mitral regurgitation. Lack of significant left atrial enlargement indicates the current risk for complication is low. No concurrent issues such as systolic dysfunction or pulmonary hypertension are noted in this study. Compared to the prior report, findings appear similar.

In a dog with no significant left atrial enlargement, no cardiac medications are clearly indicated. Assessment of progression in the future will help predict long term prognosis, which is highly variable at this stage (B1). Omega fatty acid supplementation and mild salt restriction may be of some long-term benefit. Monitor for development of a cough, labored breathing, exercise intolerance or collapse episodes.

Ventricular premature contractions (VPCs) are noted on the ECG, as were also documented previously. VPCs are generated from abnormal conductive or fibrotic tissue in the ventricles of the heart muscle, and even frequent single VPCs will often cause no clinical signs in dogs. When sustained however, ventricular tachycardia can lead to symptoms such as lethargy, collapse and sudden death. VPCs are a very non-specific finding. They can be due to significant cardiac disease (mild in this study) or be extra-cardiac in origin, i.e., due to pain, stress, inflammation, cancer, GI disease, DIC/sepsis, etc. In this senior larger breed dog, a primary arrhythmia is possible; however, all possibilities should be considered. Full systemic evaluation is recommended (CXR, AUS, etc.). Unfortunately, there is always an elevated risk for collapse and sudden death in any arrhythmic patient, and even on medications this risk unfortunately still persists.

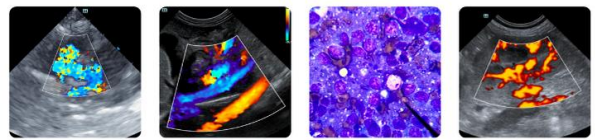
Unfortunately, the ECG provided is extremely brief and does not provide a full picture of the arrhythmia. That being said, single and couplet VPCs are noted in the very short tracing, which likely suggest inadequate control. Consider a holter monitor if possible; however, if declined a dose increase in Sotalol is recommended. An additional antiarrhythmic, such as Mexiletine, may be warranted pending results.

Fish oil supplementation is recommended for dogs with arrhythmias (500-1000mg of omega 3 and 6 once to twice daily).

Anesthetic risk is considered moderately elevated. Avoid ketamine, telazol, Dexdomitor (or other alpha-2 agonists) and acepromazine. Recommend having lidocaine CRI available for use in the event of worsening ventricular arrhythmias under anesthesia (CRI 50—75mcg/kg/min).

**PLAN**

Consider a holter monitor in this case. If declined, increase Sotalol to 30mg (1/4 of a 120mg tablet) and assess response. Reassess ECG or holter monitor in 1-2 weeks. Mexiletine may also be necessary.



## PATIENT

Bismarck Gleichmann

## SPECIES

Canine

## BREED

Australian Cattle Dog

## SEX

Male Neutered

## AGE

13 years

## WEIGHT

34lbs

## INTERPRETED BY

Maggie Machen Lamy,  
DVM, DACVIM  
(Cardiology)

## IMAGING PERFORMED BY

Cole England, DVM

## HOSPITAL NAME

Blue Cross Animal  
Clinic

## REFERRING VET

Dr. Aguirre

## INVOICE

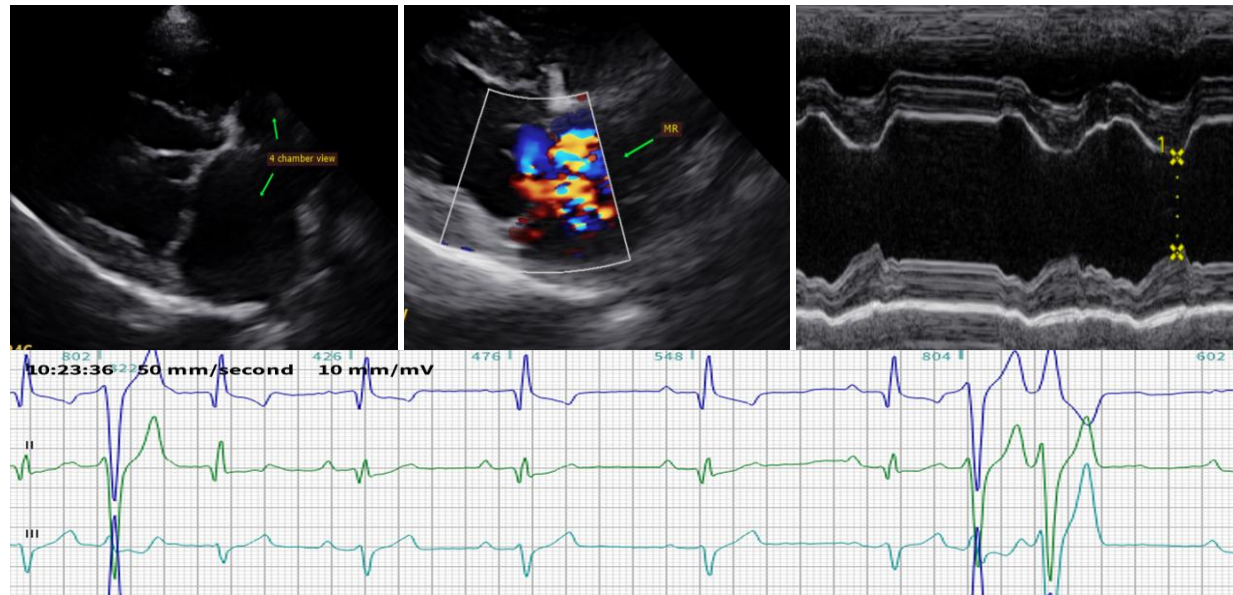
47254

## DATE

3/23/26

Recommend conservative monitoring with a recheck echocardiogram and ECG in 6 months, sooner if any development of clinical signs.

## IMAGES



**The information and recommendations provided are based on the images presented by the referring veterinarian. No evaluation can be communicated regarding pathology that was not visible in the image/video clips provided.**

Thank you for this referral. This report was generated using transcription software, and minor dictation errors may be present. If the clinical or image interpretation does not parallel your findings or if I can be of any further assistance, please contact me.

**Maggie Machen Lamy, DVM**  
**Diplomate of the American College of Veterinary Internal Medicine (Cardiology)**  
info@sonopath.com